

# OCULAR SURGERY NEWS

January 1, 2005

The New Refractive Option:

# Iris-Fixated Phakic IOLs

Sponsored as an educational service by Advanced Medical Optics

# INTRODUCTION

Phakic IOL technology is an alternative treatment for patients with myopia, hyperopia and astigmatism. First introduced in 1978 for the correction of aphakia, the phakic IOL already has a successful 18-year track record in Europe. According to the National Eye Institute, myopia affects up to 25% of the U.S. adult population. Thus, phakic IOL technology fills a need for additional treatment approaches for the correction of refractive errors. On Sept. 10, 2004, the Food and Drug Administration (FDA) approved the Verisyse phakic IOL (Advanced Medical Optics [AMO], Santa Ana, Calif.). This roundtable symposium addresses the clinical aspects, surgical techniques and ongoing research associated with phakic IOLs, while specifically addressing the treatment of myopia with the Verisyse phakic IOL.

Richard L. Lindstrom, MD  
Chief Medical Editor  
OCULAR SURGERY NEWS



## Moderator

**Richard L. Lindstrom, MD**  
Chief Medical Editor, OCULAR SURGERY NEWS




**Kerry K. Assil, MD,**  
is the medical director for the Assil Sinskey Eye Institute in Santa Monica, Calif.



**Elizabeth A. Davis, MD,**  
is assistant clinical professor of ophthalmology at the University of Minnesota and is a practicing ophthalmologist at Minnesota Eye Consultants in Minneapolis.



**Eric D. Donnenfeld, MD,**  
is the medical director of the TLC Laser Center in New York. He is also a partner with Ophthalmic Consultants of Long Island and Connecticut and is on the Cornea/External Disease editorial advisory board of OCULAR SURGERY NEWS.



**John D. Hunkeler, MD,**  
is chairman of the Department of Ophthalmology at the University of Kansas School of Medicine and is the founder and medical director of the Hunkeler Eye Institute in Overland Park, Kan.



**Francis W. Price, MD,**  
is president of the Price Vision Group in Indianapolis, Ind.



**R. Doyle Stulting, MD, PhD,**  
is professor of ophthalmology at Emory University School of Medicine and is a practicing ophthalmologist at Emory Vision Correction Center in Atlanta, Ga.

# The New Refractive Option: Iris-fixated Phakic IOLs

## Patient criteria for phakic IOL implantation

**Richard L. Lindstrom, MD:** Verisyse (Advanced Medical Optics [AMO], Santa Ana, Calif.) is the first approved phakic IOL approved by the Food and Drug Administration for the correction of myopia from 5 D to 20 D. What are your patient criteria for implanting a phakic IOL?

**Eric D. Donnenfeld, MD:** A variety of patients are good candidates for phakic IOL implantation. Generally, patients who have higher degrees of myopia are not candidates for LASIK or PRK. These patients will now be able to achieve visual clarity, better contrast sensitivity and a higher quality of vision with phakic IOLs. Additionally, patients who are contraindicated for laser corneal ablative procedures because of thinner corneas or topographic irregularities will benefit from phakic IOL implantation.

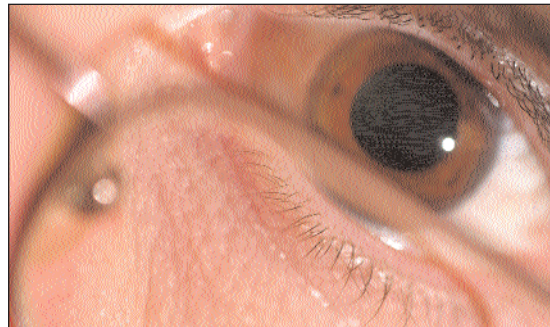
**Elizabeth A. Davis, MD:** I would consider implantation with the Verisyse IOL for any patient whose refractive error is -8 D and higher. The highest degree of myopia that I will treat with a laser corneal ablative procedure is 12 D for patients who have no other contraindications.

**Francis W. Price, MD:** Phakic IOLs definitely seem to provide a better quality of vision than laser refractive surgery for those with refractions of minus 10 D or more. They may also be better for those over 8 D, but that still may be debatable. I also recommend the Verisyse for any one over 5 D of myopia whose corneas may be too thin for laser refractive surgery, or who may have questionable topography.

**R. Doyle Stulting, MD, PhD:** When determining whether a patient is a candidate for phakic IOL implantation, I will consider not only refractive error, but also corneal thickness, topography and keratometry readings. Patients with thin corneas are not good candidates for LASIK because these are risk factors for ectasia. Patients with high myopia and flat

corneas may have poor quality of vision after LASIK.

**Kerry K. Assil, MD:** For patients with refractive errors higher than 10 D, I will implant the Verisyse IOL. Between 7 D and 10 D of refractive error is a gray zone and my procedure depends upon corneal



**Phakic IOLs definitely seem to provide a better quality of vision than laser refractive surgery for those with refractions of minus 10 D or more.**

— Francis W. Price, MD

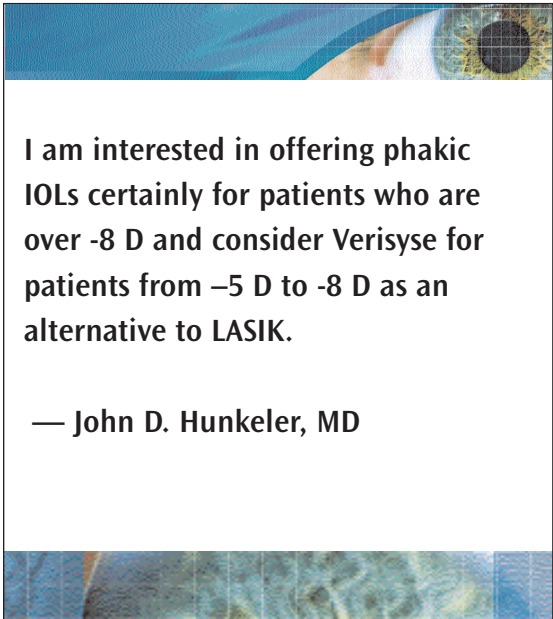


thickness, pupil size, anterior chamber depth and corneal curvature. For eyes with thinner corneas, larger pupils, deeper chambers and flatter corneas I will implant the Verisyse. Below 7 D of refractive error, I will typically perform LASIK or PRK. The only exception is when a patient has mild corneal ectasia — if this is the case, I will implant the Verisyse down to 5 D of refractive error.

**Lindstrom:** Dr. Hunkeler, your practice has focused on cataract surgery for some time. With the approval of the Verisyse, your patient base will expand to include patients who are seeking refractive

procedures. At what level refractive error would patients have to be for you to begin discussing phakic IOLs?

**John D. Hunkeler, MD:** My personal practice has focused on cataract surgery for over 30 years but I also monitored refractive surgery and oversaw the development of PRK and LASIK and monitored this



**I am interested in offering phakic IOLs certainly for patients who are over -8 D and consider Verisyse for patients from -5 D to -8 D as an alternative to LASIK.**

— John D. Hunkeler, MD

carefully. As a result, I am interested in offering phakic IOLs certainly for patients who are over -8 D and consider Verisyse for patients from -5 D to -8 D as an alternative to LASIK.

**Lindstrom:** It is my understanding that approximately 20% of the surgeons who have expressed interest in phakic IOL courses are actually cataract surgeons who do not perform laser refractive surgery.

**Donnenfeld:** The approval of a phakic IOL instantly provides surgeons who have essentially ignored refractive surgery for the last 10 years the opportunity to perform refractive procedures. Implanting phakic IOLs does not involve a new skill set for cataract-only surgeons — in fact, many of the techniques that they have perfected over the years will help to ensure the safety of the procedure.

**Lindstrom:** I would estimate that most surgeons who are currently performing laser surgery would continue to use laser surgery for patients up to -8 D to -10 D. Dr. Hunkeler, because you do not perform

laser refractive surgery, would you implant the Verisyse in a patient with myopia as low as 5 D and who would otherwise be a candidate for laser surgery?

**Hunkeler:** That is not correct. I now perform LASIK and, based on information from John Vukich, MD, comparing phakic IOLs to LASIK, even lower levels than -8 D to -12 D would have better visual outcome with the phakic IOL than LASIK.<sup>1</sup> I will be comfortable offering LASIK up to -7 D to -8 D but for lower powers, I will recommend LASIK.

**Assil:** During the clinical trials with the Verisyse IOL, one of our biggest challenges to find patients who were willing to have this IOL implanted because they had never heard of it. One of the benefits of FDA approval is that it has increased public awareness to the point where patient are asking to have the Verisyse implanted without solicitation. Ironically, I am finding that a small subset of patient who ask for the Verisyse have only 2 D or 3 D of myopia and they are disappointed that I will not implant a phakic IOL.

**Price:** It will be interesting to see how LASIK will stand up to the competition of phakic IOLs because the IOLs are so stable and predictable.

**Lindstrom:** I agree. Additionally, the quality of vision with phakic IOLs is high.

**Price:** With LASIK, as the amount of correction increases, the amount of scatter from the intended correction increases regardless of the platform that is used. However in the Verisyse study, we have found that the results are very consistent and close to the intended correction regardless of the amount of refractive error and the quality of the visual result was excellent even with the higher amounts of correction.

**Donnenfeld:** In any refractive procedure, I am most concerned with how the cornea looks after surgery. In the past, refractive surgeons have adhered to an unwritten rule that corneas should be no flatter than a keratometry reading of 35 D or 35.5 D after surgery because the postoperative visual degradation in flatter corneas is significant.

Perhaps we should strive for keratometry readings of 36.0 D or 36.5 D instead and use phakic IOLs to improve the quality of vision for these patients. Patients who have keratometry readings between

39 D to 40 D with a refractive error of -6 D may have better results with a phakic IOL than with LASIK. The postoperative cornea should be a consideration when deciding between these two procedures.

**Lindstrom:** Another type of patient who will benefit from Verisyse phakic IOL technology is one with thinner corneas. Currently, patients who are -6 D and who have corneas in the range of 480  $\mu$ m to 500  $\mu$ m would not be good candidates for laser ablation.

**Hunkeler:** I believe a significant number of patients who have avoided laser correction will now be drawn to phakic IOL implantation.

**Price:** One of the major advantages to phakic IOL implantation is that it is reversible, which is helpful for a patient who later develops a cataract. The lens can easily be removed and it does not complicate the calculation for the pseudophakic correction as LASIK and PRK often do.

**Lindstrom:** What are the contraindications for implanting a phakic IOL?

**Donnenfeld:** First, patients with a pre-existing cataract would not be candidates for this procedure and should consider other refractive options. Second, while long-term follow-up with the Verisyse has shown little endothelial cell loss over time, patients who have pre-existing Fuchs' dystrophy or a low endothelial cell count would not be good candidates for phakic IOL implantation. Additionally, patients who have a history of or ongoing chronic inflammation, persistent uveitis, iritis, significant wound-healing abnormalities, rubeosis irides, significant macular degeneration or corneal irregularities would not be candidates. In my opinion, surgeons who are considering this procedure should have a specular microscope in their office or be comfortable performing specular reflection.

**Price:** Two other contraindications for phakic IOL implantation are a shallow anterior chamber (less than 3.2 mm) and a large pupil diameter (larger than 7 mm).

**Lindstrom:** The FDA trial for Verisyse was based on 5-mm and 6-mm optic lenses. The trial guidelines indicated that patients whose pupils were larger than the optic size in mesopic conditions should not be implanted with the IOL. The most common

postoperative side effect with Verisyse is nighttime halos, which may be related to pupils dilating out past the optic edge.

In LASIK, night vision symptoms are not correlated to pupil size, but to residual myopia, astigmatism or various optic aberrations (personal communication, 2004). I believe that this will also be found to be the case with the Verisyse.

I will implant the Verisyse in patients with larger pupils, but require informed consent before doing so.

**Donnenfeld:** A scotopic pupil should be no more than 1.5 mm larger than the size of the IOL. If a patient has a 7.5-mm pupil, I then am comfortable implanting a 6-mm optic IOL.

**Assil:** In the clinical trials, we noted greater degrees of glare and halos associated with 5-mm vs. 6-mm optics. A centered 6-mm IOL seems to be tolerated well, even in eyes with an 8-mm pupil. I found that glare is more often associated with an over-aggressive peripheral iridectomy (PI) than it is with a mismatch between pupil and optic size, as long the optic is well-centered over the entrance pupil. And so, for that reason, I've switched to doing exclusively inferior PIs.

**Hunkeler:** A major contraindication for LASIK is dry eye. Is dry eye an indication for phakic IOL implantation for patients who would otherwise be candidates for LASIK?

**Donnenfeld:** For a patient who has pre-existing dry eye and wants refractive surgery, I would consider a phakic IOL. Phakic IOL implantation does not change the corneal contour, normal tear mechanisms are kept in place and, postoperatively, the lid moves over the cornea normally, so dry eye is neither induced nor exacerbated.

### **Patient management with phakic IOLs**

**Lindstrom:** When you have a good candidate for the Verisyse, what are the key issues in informed consent?

**Davis:** First, I will discuss vision-threatening complications such as the risk for infections and cataract formation. I will also discuss retinal detachment — although Verisyse is not associated with this complication, any patient who has a high degree of myopia will be at higher risk for retinal detachment over the course of their lifetime, independent of surgery. I

clarify this with patients because they typically attribute negative postoperative events to the procedure when this is not always the case.

**Donnenfeld:** Patients who are more than -8 D and want a refractive procedure I refer for a preoperative retinal consultation. I also instruct patients postoperatively that they will continue to have added risks because of the nature of high myopia. These patients should have routine ophthalmic evaluations.

**Davis:** It behooves every surgeon to bring up the potential for loss of vision and impress upon each patient the seriousness of the surgery. I also discuss the side effects, such as glare and halos, that are associated with every type of refractive surgery. There is also a potential for bleeding or inflammation from this procedure, as well as the possibility for overcorrection or undercorrection, both of which may require either IOL exchange or LASIK enhancement.

I discuss the importance of protecting the eye after surgery with all patients who undergo a cataract or refractive procedure.

**Donnenfeld:** I have found that the informed consent procedure for the Verisyse phakic IOL is a combination of the discussions that I have with my cataract and laser refractive surgery patients. I talk to patients about some of the risks associated with an intraocular procedure, but most of my time is spent on the risks and benefits of the refractive procedure, including glare and halos, as well as the possibility that the patient may need an enhancement postoperatively.

**Stulting:** Candidates for phakic IOL implantation must know is that a phakic IOL may not completely correct their refractive error and that the incision itself may induce astigmatism. Patients must be aware that they may have residual myopia or hyperopia postoperatively. The surgeon must also explain that intraocular surgery carries with it the potential risk of infection, cataract formation and damage to the cornea. While these complications are unlikely to occur, patients must be informed of the risk.

The retinal detachment rate is not significantly different from that which is seen in patients with myopia. However, I will still include this risk in our informed consent because patients with high myopia who have retinal detachments after phakic IOL implantation may attribute the detachment to the phakic IOL.

**Lindstrom:** How do you counsel patients on the topic of visual recovery and when they can resume their normal activities?

**Davis:** Visual recovery is fairly quick in eyes that are implanted with Verisyse. Most patients are functional the next day after surgery. However, the final visual outcome might not occur until I remove the three sutures at the 6-week postoperative visit. I also tell patients to avoid any heavy exertion for the first 2 weeks.

**Stulting:** I tell patients that postoperatively, they will see an immediate improvement in their uncorrected visual acuity (UCVA) if their surgery was performed under topical anesthesia. If their surgery is performed under local anesthesia, I will tell them that their UCVA will improve 1 day postoperatively. Generally, patients are able to resume normal activities within 1 day.

**Lindstrom:** How long do you wait before implanting the Verisyse in the fellow eye?

**Davis:** I typically wait 1 week before performing another surgery, but I may consider performing surgery even earlier in certain cases. In Europe, some surgeons are performing bilateral procedures under general anesthesia. Although I will not perform bilateral surgery, I would consider shortening my waiting time to a few days for certain patients who make this request.

**Assil:** There are some surgeons who are already performing bilateral implantation with the Verisyse IOL. However, I would caution against this — I currently am implanting them 1 day apart. I find that waiting 1 day is significant because a small number of patients are at risk for acute IOP spikes and severe inflammation.

**Lindstrom:** What kind of anesthesia do you use to perform Verisyse implantation?

**Price:** I offer my patients a choice between a general or topical anesthesia. However, no patient has requested general anesthesia in several years. I have administered general anesthesia in the past because some patients had difficulty laying still for the procedure. Most cases are easily handled with topical anesthesia. I use pledgets soaked in Xylocaine 2% (lidocaine, AstraZeneca) on the site where I will make my

posterior limbal incision. There are several advantages to topical anesthesia, including the ability to have the patient change their direction of gaze as needed during the procedure for wound construction, lens insertion and such. I have not found problems with patient discomfort either during the wound manipulation or enclavation of the lens.



**The surgeon must also explain that intraocular surgery carries with it the potential risk of infection, cataract formation and damage to the cornea. While these complications are unlikely to occur, patients must be informed of the risk.**

— R. Doyle Stulting, MD, PhD

**Davis:** I prefer to use a peribulbar block. Although I have not performed any procedures with general anesthesia, I would not hesitate to use it for a patient who is unable to remain still.

**Donnenfeld:** I also perform all my cases with a peribulbar anesthesia. For new surgeons, it is important to differentiate between retrobulbar and peribulbar anesthesia. Patients with high degrees of myopia have long eyes, so a blunt-tip needle should be used instead of considering a retrobulbar injection. I could administer topical anesthesia, but my patients who are receiving the Verisyse IOL are typically younger so I have greater concern about movement and resulting damage to the crystalline lens.

**Lindstrom:** Do you use preoperative eyedrops?

**Stulting:** I use topical antibiotics preoperatively and topical antibiotics with steroids and non-steroidal anti-inflammatory drugs (NSAIDs) postoperatively.

**Donnenfeld:** Preoperatively, my two primary concerns are to prevent infection and to make the procedure as comfortable as possible for the patient. To address these concerns, I use a preoperative antibiotic and an NSAID. Using an NSAID for several days preoperatively yields a more comfortable eye, so I use both Zymar (gatifloxacin, Allergan) and Acular LS (ketorolac tromethamine 0.4%, Allergan), four times a day, beginning 3 days prior to surgery.

**Lindstrom:** I agree that patients should be treated with preoperative antibiotics and NSAIDs. I follow the same regimen as Dr. Donnenfeld, except that I also pretreat with a steroid on the day of surgery.

Dr. Price, do you constrict the pupil?

**Price:** I have performed some Verisyse implantations without constricting the pupil because the bright lights of the microscope often create enough constriction. However, I have found that some patients can dilate during the case if pre-operative pilocarpine is not used. As a result, in most cases I use 1% pilocarpine preoperatively two times in the operating room. However, I am hesitant to use pilocarpine on patients with significantly high myopia.

**Davis:** I use one drop of 1% pilocarpine preoperatively and I supplement it with intraocular Miochol-E (acetylcholine chloride, Novartis Ophthalmics) because peribulbar anesthesia typically causes some pupil dilation.

**Lindstrom:** I use Isopto Carbachol (carbachol, Alcon Laboratories, Inc.) rather than Miochol because of its longer duration of action. One of my concerns is the postoperative IOP spike and I have found that Isopto Carbachol and 1% pilocarpine are effective tools.

**Assil:** I use 2% pilocarpine prior to the capsulotomy and Miochol-E intraoperatively. I do not recommend using topical anesthesia because the Miochol-E will cause significant ciliary pain because of the intense constriction of the pupil. Instead, I use intracameral lidocaine.

## Surgical techniques

**Lindstrom:** How do you create the incision for implanting the Verisyse?

**Hunkeler:** I perform an abbreviated limbal perimetry, cauterize the limbus and make a groove in the posterior limbus dissecting into the clear cornea with the appropriate diamond paracentesis on each side. A keratome entry is made in the center of the 5.5-mm or 6.0-mm superior incision.

**Donnenfeld:** I prefer to use a three-plane limbal incision with a 2.65-mm keratome, which I also use for cataract surgery. However, I differentiate the incision for the Verisyse by extending it to the left and the right. I then use 10-0 polypropylene sutures to close the wound, which works well.

**Davis:** I use a limbal incision and suture the wound with three interrupted 10-0 polypropylene sutures.

**Stulting:** I create a tri-plane incision in clear cornea with metal blades at the limbus centered on the steep meridian to reduce postoperative astigmatism. The incision closes easily with two or three interrupted 10-0 nylon sutures.

**Lindstrom:** What is enclavation?

**Price:** Enclavation refers to the means of fixation of an iris-fixated IOL. The Verisyse has split haptics that come together when the IOL is implanted. To fixate the Verisyse, the surgeon must use an enclavation tool to capture a “knuckle” of the iris (Figure 1) and bring it up so that the two sides of the split haptic come to rest underneath the knuckle, thus fixating in the iris (Figure 2).

While it has been suggested that this method of fixation may cause the haptics to rub against the iris, leading to inflammation and, eventually, a free-floating IOL, I have been implanting the Verisyse for 6 years and have seen no evidence of any damage to the iris. Additionally, the fixation is permanent — the IOL does not drift or pull loose with accommodation or tension to the pupil.

**Lindstrom:** What about the Verisyse makes you feel comfortable that this will be a long-term solution for your patients?

**Davis:** I have to admit that before I began implanting the Verisyse, I was skeptical about its abilities to

work long- or even short-term. However, I have been implanting this IOL since 2000 and when I see patients from 4 years ago, the Verisyse remained well fixated with stable and excellent visual outcomes.

A few years ago, I had the opportunity to speak with the inventor of the iris-fixated phakic IOL, Jan G. F. Worst, MD, at the American Academy of Ophthalmology annual meeting. He said that he has performed follow-up on patients in whom he implanted the Verisyse 20 years ago in pseudophakic or aphakic situations. He has seen no progressive damage to the iris in any of these patients and the IOLs look as if they were implanted yesterday. This indicates that the Verisyse has excellent long-term stability.

**Lindstrom:** The anterior iris is a much tougher tissue than had been anticipated. Dr. Worst has made claims to suggest that the mid-peripheral portion of the iris, where the Verisyse’s split haptics attach, is relatively immobile. This may be one of the reasons that the Verisyse is better tolerated than iris-supported IOLs.


Dr. Hunkeler, you have performed many IOL implantations over several decades. Do you feel comfortable that the Verisyse is a long-term solution for patients?

**Hunkeler:** The procedure of reversing the enclavation is straightforward. I predict that when a surgeon performs cataract surgery on an eye with a Verisyse IOL, the implant will be easily removed and the cataract procedure performed. Because I tend to perform these procedures superiorly, I will remove the Verisyse through the previous superior incision and switch to a clear corneal temporal incision for the cataract procedure. I have used this in one case with good results.


**Donnenfeld:** The track record of the Verisyse in Europe is longer than many of the anterior and posterior IOLs that we commonly implant. The Verisyse FDA trial was one of the largest ever performed — these parameters all show that this IOL stands the test of time.

When the Verisyse is implanted, the pupil continues to function normally. Fluorescein angiography has been performed and no iris leakage has been detected. Finally, postmortem studies have been performed on patients implanted with the Verisyse.

**Stulting:** Over 100,000 Verisyse phakic IOLs have been implanted outside of the United States by over



**Figure 1.** The enclavation tool is used to lift a portion of the iris.



**Figure 2.** Once enclavated, the IOL's split haptics come to rest underneath the "knuckle" of iris.

*Figures 1 and 2 courtesy of AMO.*

5,000 ophthalmologists with no reports of long-term complications. It is rare for clinicians to have this much long-term experience with a newly approved device in the United States. The extensive non-U.S. experience with this IOL makes me comfortable with its safety profile.

**Lindstrom:** Dr. Donnenfeld, please describe your implantation procedure with the Verisyse IOL.

**Donnenfeld:** I perform a YAG peripheral iridotomy superiorly the day of surgery. I implant the Verisyse through a superior incision. I place my enclavation incisions at 10 o'clock and 2 o'clock and bevel the incisions minimally with a 1.2-mm diamond keratome. My goal is to aim the incisions toward the peripheral iris at 3 o'clock and 9 o'clock. I place Miochol-E in the anterior chamber and then Healon (AMO). I enter the eye with my dominant hand holding the enclavation needle first. I then grasp the IOL with my nondominant hand using Budo forceps and, while holding the IOL in place, I use my enclavation needle to push the iris in a "snowplow" maneuver, in which I actually

push the iris so that a portion of the tissue is pushed upwards and into the split haptics. The snowplowing force also moves the haptics as if a gate is opening, enabling them to catch onto the iris tissue.

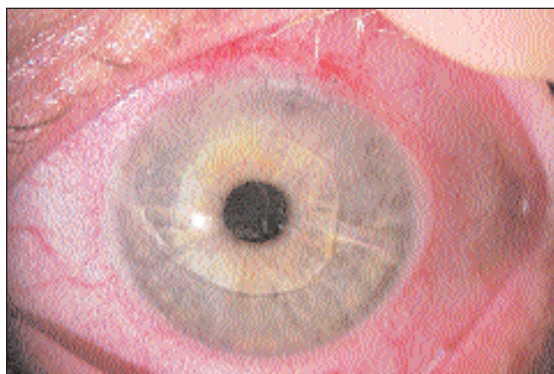
If I find that, after enclavation is complete, I need to add or subtract the amount of iris that has been caught in the split haptics, I can go back and, with multiple passes, make the necessary adjustments. I remove the Healon with an irrigation and aspiration cannula and suture the wound with three 10-0 nylon sutures (Figure 3).

My main concern with this procedure is that my nondominant hand is able to hold the IOL steadily, so I hold the Verisyse at the iris plane or lower. The normal reflex of a surgeon is to enclavate superiorly, but this will result in a decentered IOL. Thus, I prefer to either directly center the IOL to the pupil or to center inferiorly, so that the superior eyelid will cover the IOL.

**Assil:** With respect to wound closure, I recently switched to using 10-0 vicryl sutures because they do not require removal. I continue to use a figure-8 stitch, entering through the cornea and exiting through the sclera. I then grasp the suture as second time through the cornea and out through the sclera and tie it off, rotating it towards the conjunctival side. Besides not requiring removal, vicryl sutures seem to induce a mild degree of wound inflammation, which is good for firm adhesion. The drawbacks to vicryl sutures include a greater tensile strength than nylon, increasing the possibility of greater degrees of cylinder postoperatively, and that the material is slightly less visible to the surgeon's eye while performing the procedure.

**Lindstrom:** I do not think that implantation of the Verisyse will present any difficulties for the experienced anterior segment surgeon, except that the IOL must be passed up and over the crystalline lens, then rotated to where it is parallel to the incision.

**Assil:** The best way to ensure that the crystalline lens will not be in any way traumatized during IOL insertion is to have a myotic pupil and a sufficiently large opening to insert the IOL. I achieve this by first inserting a 2.5-mm keratome, immediately followed by a 6-mm keratome. I then grasp the optic of the IOL closer to proximal haptics, pointing toward myself rather than the central belly of the IOL. I grasp the optic in this way because during IOL insertion, the volume of the IOL does not compete with



**Figure 3.** In the above figure, a clear corneal incision was closed with three 10-0 nylon sutures and the Verisyse is centered in the eye.

*Figure 3 courtesy of Eric D. Donnenfeld, MD.*

the insertion forceps. Thus, the interior haptics and the inferior portion of the optic have already cleared the pupil by the time the insertion forceps arrive at the wound, at which point I can either continue to insert the IOL entirely or I can simply let go and push the remainder of the IOL into the anterior chamber.

### Surgical pearls

**Lindstrom:** What pearls do you have to help surgeons navigate enclavation better?

**Assil:** It is important to remember that when the pupil is constricted, the surgeon must adjust for the inherent slight movement both nasally and superiorly. Intraoperative Miochol-E or Miostat (Carbochol, Alcon Laboratories), as well as stab incisions, viscoelastic and the opening of the eye, will cause the pupil to move even more. Because of these factors, the eye must be marked on the conjunctiva near the limbus in three locations — two on the horizontal, just below the midline of the pupil and the third inferiorly, just temporal to the vertical midline of the pupil. The inferior mark should be temporal to the vertical midline of the pupil because the pupil has moved nasally from constriction. The reason the two in the horizontal midline should be below midline is threefold. First, the pupils move superiorly from pilocarpine or Miochol-E. Additionally, the tendency in enclavation is to feed the iris from above, through the haptics, which causes the IOL to progressively migrate superiorly. Lastly, if the IOL is off center, it is better to have it be slightly below midline than above, because superiorly, the upper lid will cover the edge of the IOL. Thus, marking is critical to the success of enclavation.

The enclavation calipers should be used to mark

an 11-mm cord length superiorly at the limbus, and the 15°-blade should enter centrally at the ink marking with its cutting edge so that the incision expands centrally as it is made. The 11-mm cord length defines the outer limits of the distance between the enclavation paracentesis sites. The direction of the blade should be oriented towards the position of enclavation, meaning that rather than entering radially like we do with cataract surgery, if we enter at the 2 o'clock position the blade should be aiming more towards 4 o'clock. If we enter at 10 o'clock, we should be aiming more towards 8 o'clock. Furthermore, a long-tunnel paracentesis is undesirable because the enclavation needles will become oar-locked, either making it difficult to get underneath the haptics or making visibility more cumbersome due to distortion of the cornea.

A moderate amount of Healon should be placed above the lens to help push the IOL against the iris to prevent against deepening the anterior chamber and causing the iris to become concave. The enclavation needle should be inserted into the eye first, followed by the optic forceps. Temporal enclavation should be performed first to help guide nasal enclavation. Because the cord length is longer temporally than nasally between the enclavation point and the chamber angle, any tugging on the IOL during secondary enclavation will not traumatize the iris root.

The surgeon must not rush the enclavation procedure. If too much iris is passed through the haptics in one motion, the surgeon risks the possibility that the haptics will grasp full thickness of iris rather than iris stroma. Three or 4 passes should be made before the haptics are securely fastened.

**Hunkeler:** One of the most important things is to ensure that the IOL is not damaged while taking it out of the container or during insertion. With foldable lens implants, the surgical technician loads the foldable lens into the inserter. With the Verisyse, the surgeon must grasp the IOL and its angle edges can make this more challenging.

I would recommend grasping the IOL at the edge of the optic near the base of the haptic and then sliding the implant into the anterior chamber. I prefer to temporarily close the lateral sides of the incision with sutures to maintain absolute control of the chamber depth. Additionally, temporal closure of the lateral sides with sutures does not require additional Healon insertion during the enclavation. This is a safety feature for surgeons who are learning to implant the

Verisyse because he or she can avoid viscoelastic or iris egress during the enclavation.

**Stulting:** Placement of the viscoelastic is critical. It is best to inject a small amount of Healon, enough to protect the endothelium but not so much that the iris position is distorted.

When positioning the IOL, the surgeon should note the iris anatomy and identify the optical enclavation points. Bimanual dexterity is necessary for the enclavation procedure. The IOL must be held in position away from the cornea and the crystalline lens. The second hand is used to create and lift a knuckle of the iris.

**Davis:** I make my incision superiorly at 12 o'clock. I find it easier to insert the IOL while inferiorly rotating the eye. Otherwise, the brow gets in the way, particularly in deep-set eyes.

Also, Healon should always be injected on top of the IOL, so that the lens floats downward toward the iris and the endothelium is protected.

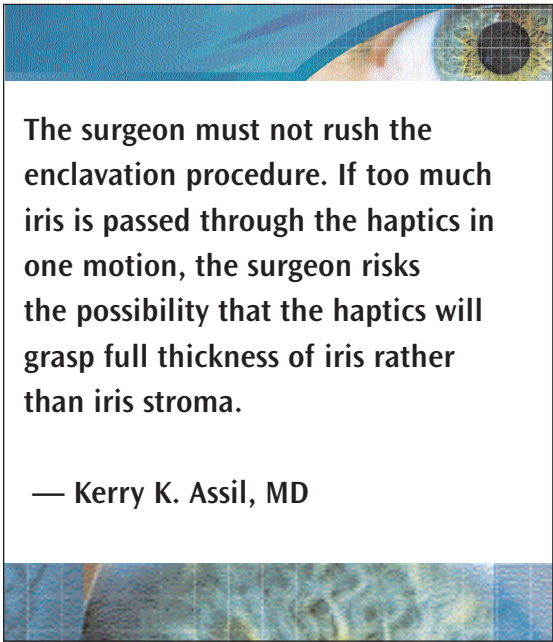
Finally, during enclavation, it is important to pick a landmark on the iris to target. Unless the surgeon uses sutures particularly close to the wound to stabilize the anterior chamber, when the Budo forceps are used to grab the IOLs, some viscoelastic normally comes out. This causes the chamber to shallow and the implant will shift slightly.

**Price:** Because I use topical anesthesia, it is easy to have the patient look down during the incision. Before I make the incision, I mark the limbus at the location where I want to fixate the IOL, usually 3 o'clock and 9 o'clock.

The placement of the paracentesis is also important. Incisions for cataract surgery often move parallel to the iris, whereas when implanting the Verisyse, it is better to angle the incision downward, especially for the nasal side where nasal displacement of pupil is common causing the site of enclavation to be closer to the angle and the paracentesis site.

Surgeons must consider where the enclavation will occur — I have found that if I place my paracentesis track too far central in the cornea as compared to keeping it peripheral and close to the limbus, the corneal surface becomes distorted during enclavation and the procedure is hard to visualize. I prefer beginning on the nasal side because it is more difficult to place the first haptic due to the nasal displacement of the pupil.

**Lindstrom:** I always insert the enclavation needle first and reach in and grasp the optic second. I enclavate with my dominant hand and, when the iris is fixated with the IOL, I rotate the IOL with the enclavation needle to center it. Usually, I will have to inject more Healon in over the optic and push it down before I enclavate the other side of the iris.



**The surgeon must not rush the enclavation procedure. If too much iris is passed through the haptics in one motion, the surgeon risks the possibility that the haptics will grasp full thickness of iris rather than iris stroma.**

— Kerry K. Assil, MD

If I am not satisfied with the centration of the IOL, I will undo the enclavation on the left side and redo it on the right side, because I am right-hand dominant.

**Donnenfeld:** Once a surgeon has taken a course in how to implant the Verisyse or has observed a procedure, it is easy to become comfortable with the surgery. I apply Healon two to three times during the procedure to maintain a deep anterior chamber. However, I am careful not to overfill the eye and to place the Healon on top of the IOL to force it down toward the iris.

The biggest mistake that surgeons make when implanting the Verisyse is trying to use the enclavation needle to insert the iris into the split haptics. This technique is incorrect. The iris should come up with the snowplow motion and the haptics should fall into place.

**Lindstrom:** After I have placed the IOL and the haptics are fixated in the iris, I perform a small surgical peripheral iridotomy. However, some surgeons prefer to perform Nd:YAG laser iridotomy preoperatively.

Dr. Price, what is your preference?

**Price:** One of the advantages to the Verisyse procedure is that it allows a surgical iridotomy as the last step. I would think most surgeons, especially high-volume surgeons, would prefer to not have to perform two surgeries, such as one would have to do with preoperative Nd:YAG laser iridotomy.

**Hunkeler:** As a matter fact, during my routine surgical day I perform Nd:YAG capsulotomies between patients, so adding an additional YAG laser iridotomy would not interfere with my workflow.

The surgeon can perform a laser iridotomy or a surgical iridectomy but either of these procedures is necessary to reduce the likelihood of an IOP spike after the procedure from pupillary block.

**Lindstrom:** If a surgeon were to forget to perform either the iridotomy or iridectomy, what would be the best course of action? Would you perform an Nd:YAG laser iridotomy later?

**Donnenfeld:** For beginning surgeons, performing a PI is a good strategy because it is an easier procedure. I perform Nd:YAG laser iridotomy with two pulses per burst of 4 milliJoule (mJ) to 5 mJ and pass through the iris with one or two shots of the laser, depending on the color of the iris. This is an easy, 1-minute procedure.

**Lindstrom:** In terms of surgical tools, I prefer to use a cohesive viscoelastic such as Healon. Verisyse implantation is not a good setting for Healon5 (AMO) because of the potential IOP spikes during this procedure. How do you remove Healon?

**Price:** I irrigate Healon out through the paracentesis. Although some patients experience discomfort with this method, there have been no IOP spikes in my patients. Early in the FDA clinical trial, it was recommended that we use Healon5 with the Verisyse. I had a case in which I used Healon5 and had problems because I could not tell if the IOL was centered during enclavation. I would not use Healon5 again when implanting the Verisyse.

**Davis:** I place three 10-0 nylon sutures in the incision and tie the central suture. Then, I use bimanual I&A. Healon comes out quickly with this method.

**Donnenfeld:** I perform two I&As. I lower the irrigation bottle farther than I do for cataract surgery, to approximately 2 feet over the patient's head, because

I want to avoid large amounts of fluid entering the eye and putting pressure on the iris. I can be more certain that the Healon is exiting the eye with I&A than I am with manual flushing.

**Assil:** I use Healon GV and a two-port I&A procedure, using a 21-gauge aspiration port and a 19-gauge irrigation port, on the paracentesis sites after closing the primary incision. The most common cause of complications from Verisyse implantation is lack of complete viscoelastic removal. This can cause spikes in IOP, papillary sphincter atrophy and loss of reactive ability of the patient's pupil.

**Lindstrom:** Dr. Hunkeler, what is the protocol for extracting a cataract from a patient with a Verisyse IOL?

**Hunkeler:** I make my routine calculations and simply enlarge the incision from what I used to implant the Verisyse. I remove the IOL, suture the incision and perform a clear corneal temporal incision for phacoemulsification.

**Davis:** Did you use the same preoperative A-scan for your IOL calculations for cataract surgery that you did for the Verisyse?

**Hunkeler:** Yes. Biometry was on target.

**Davis:** This correlation between A-scans is important because it demonstrates the need to take an A-scan prior to implanting a phakic IOL so that the A-scan can be referred to later if cataract surgery is necessary.

Does the ultrasound velocity need to be adjusted for cataract surgery?

**Hunkeler:** The ultrasound velocity varies slightly, but the IOL is so thin in the center that it makes no significant difference in the postoperative refraction.

**Assil:** I began implanting the Verisyse IOL in 1977, and have performed 10 LASIK procedures and two PRK procedures to date, with an approximate 6% to 7% enhancement rate over 7 years follow-up. I think that's an accurate number, 6% or 7%. LASIK or PRK techniques do not require any modification whatsoever in order to be performed over Verisyse implantation.

**Lindstrom:** Dr. Donnenfeld, have you performed LASIK enhancements after implanting the Verisyse?

**Donnenfeld:** I have performed one LASIK enhancement over Verisyse in a case where the IOL had been previously implanted in Europe. The results were excellent. Dr. Davis has provided positive data that show the IOL most likely will not touch the cornea because the anterior chamber deepens during a LASIK procedure.

LASIK enhancement offers the opportunity to correct minimal postoperative refractive errors after Verisyse implantation. At the same time, wavefront

myopia in Europe since 1991, so it has a long track record of good tolerance in the eye. Some ophthalmologists have bad memories of pupil-fixated IOLs and complications. The Verisyse is completely different from a pupil-fixated IOL. I had originally worried that the iris-fixation would lead to endothelial cell loss or chronic inflammation from the possible phacodynesis of the lens tugging on the iris. Has anyone seen endothelial cell loss or inflammation with the Verisyse IOL?

**The risk of inducing a cataract is lower than with posterior chamber IOLs because there is protection from the iris especially when the pupil is constricted.**

— Elizabeth A. Davis, MD

**Donnenfeld:** No. In the FDA clinical trial, endothelial cell counts were taken on a regular basis. The Verisyse is well tolerated in the eye with no cases of corneal decompensation; minimal endothelial cell loss over time that is similar to what occurs in a normal physiological eye; and in more than 1,000 cases, only three patients required cataract extraction, which is similar to non-surgical eyes. In addition, the retinal detachment rates with this lens are similar to that in non-surgical eyes.

There are no significant cornea, lens or retina complications associated with the Verisyse IOL. Any IOL that sits in the anterior chamber too close to the cornea will cause damage and IOLs that are too close to the crystalline lens will cause cataract formation, so phakic IOLs function best when placed furthest from the lens and the cornea. The iris-fixated Verisyse sits in this location.

ablation technology can be used to achieve a new level of visual acuity and quality.

**Fixation and centration**

**Lindstrom:** Are you comfortable with anterior chamber iris fixation for an IOL?

**Price:** The Verisyse’s iris-fixation is safe and the visual results have been excellent.

I am slightly biased because part of my practice over the years has included patients with complications, such as iris deformation and inflammation, due to angle-supported anterior chamber IOLs. As a result, I have not implanted an angle-supported lens since 1986.

**Hunkeler:** When implantation with the Verisyse is complete, one should be certain that the implant is properly positioned and the outcome can easily be predicted. With posterior chamber phakic IOLs, it is not possible to measure the posterior chamber size and this measurement appears to be a significant factor in cataract prevention.

**Lindstrom:** The most common complications that cataract surgeons and refractive IOL surgeons alike face are IOL subluxation or decentration and power calculation error. These will most likely be the issues that we encounter with the Verisyse IOL so surgeons are already accomplished at managing these complications.

**Davis:** I agree that iris fixation is safe and the results are good. The risk of inducing a cataract is lower than with posterior chamber IOLs because there is protection from the iris especially when the pupil is constricted.

**Donnenfeld:** Something that we have learned in refractive surgery is the importance of centering the ablation to the pupil center or the center of the wavefront map. The Verisyse is the only IOL that can be centered on the pupil.

**Lindstrom:** The iris-fixated IOL has a history dating to the 1970s and has been used to correct

**Price:** I recently implanted the Verisyse in a woman with a markedly decentered pupil. Because the surgeon decides where to fixate, or enclavate, the Verisyse lens, I was able to center the lens on her decentered pupil. This would not have been possible with other phakic lenses because IOLs which fixate either in the angle or posterior chamber of the eye by necessity center on the geometric center of either the anterior or posterior chamber, and in this case the other lenses would have been decentered relative to her pupil. Many patients have small amounts of decentration to their pupils, and the Verisyse allows us to compensate for that.

### Correcting astigmatism

**Lindstrom:** What is your technique when implanting the Verisyse in a patient with astigmatism?

**Price:** Most patients have some astigmatism. An advantage of the Verisyse lens is that we need to make either a 6 or 5mm incision. This can be used to our advantage to decrease preoperative astigmatism. I vary the degree of beveling of the incision and timing of suture removal to eliminate preoperative astigmatism. I vary the axis of the incision to correspond to the axis of the steepest keratometry reading. In cases where temporal incisions are used, I place the Verisyse lens vertically instead of horizontally, and I have seen no difference in eyes with either lens orientation.

Surgeons must remember that using a clear corneal incision increases the risk of developing flattening at the incision's axis.

**Davis:** If there is a significant amount of astigmatism, I prefer to use a limbal incision so that, if I operate on the axis, some of the astigmatism will be addressed. However, if there is astigmatism postoperatively, I usually manage it with LASIK.

**Lindstrom:** Do you make an intraoperative limbal relaxing incision or perform astigmatic keratotomy (AK)?

**Davis:** No. I find that LASIK is more predictable once I know the patient's exact refractive error and also allows me to address any residual spherical error.

**Donnenfeld:** Most patients who are highly myopic also have small amounts of cylinder, so I make most of my incisions superiorly and cut my sutures earlier

for 1 D or less of cylinder. When the patient has 1 D to 3 D of cylinder, I make a standard superior incision and add a limbal relaxing incision during surgery. If more than 3 D of cylinder is present, I prefer to perform a limbal relaxing incision preoperatively. I wait 1 month to perform the phakic IOL implantation. I will also make the incision larger than I would normally, because there is a coupling effect with larger cylindrical corrections — I can then apply LASIK to the patient after the IOL implantation.

**Hunkeler:** I use a superior incision and prefer to leave the polypropylene sutures in place because they tend to last indefinitely. I try to adjust the suture tension enough so that there is no induced cylinder and that it is not necessary to remove the sutures at a later time. Necessary astigmatic keratotomy may be performed to help reduce cylinder as well as LASIK for cylinder and spherical cylindrical errors post-operatively.

**Lindstrom:** It seems that to achieve good uncorrected visual acuity with phakic IOLs, 1 D or less of astigmatism is needed.

### Clinical results with phakic IOLs

**Lindstrom:** Dr. Donnenfeld, please discuss the U.S. clinical trial for Verisyse.

**Donnenfeld:** There were actually two U.S. clinical trials reported for Verisyse. The first was an enrollment trial for visual outcomes and the second was a safety enrollment trial. A total of 684 patients were enrolled between 1997 and 2003 and 478 of these patients were bilaterally implanted. Patients older than 21 years of age and younger than 50 years of age and with less than 2.5 D of cylinder were implanted with the Verisyse to correct between -5 D and -20 D of refractive error. The most common IOL implanted was 13 D, so it is clear that most patients in the trial had high degrees of myopia.

**Stulting:** The results of the trials showed that almost all the patients achieved best-corrected visual acuity (BCVA) of 20/40 or better. The most impressive aspect of the postoperative results was that 49% of the patients who had the Verisyse phakic IOL implanted gained one to two lines of visual acuity and 2% of patients gained more than two lines of BCVA. Only 6% of patients lost either one or two lines of BCVA. Ten percent of patients gained more than 2 lines of visual acuity in the trial.

**Donnenfeld:** I have never seen refractive outcomes analysis this favorable, which speaks to the superior quality of vision that the Verisyse provides patients. The follow-up showed that the stability of refractive results is also excellent. Eighty-six percent of patients who achieved less than 1 D of hyperopia or myopia were followed up for 3 years and showed almost no difference between day 1, month 1 and year 3. Additionally, patient satisfaction was high with the Verisyse. Some patients experienced glare and halos after implantation, but the effects were similar to what they experienced preoperatively.

The complications that were associated with the Verisyse were minimal in the clinical trials. Early on, some of the patients required re-enclavation, but after several procedures were performed this was no longer necessary in any patients.

**Stulting:** A small number of patients developed cataracts — only 3 cataracts out of 1,179 patients enrolled required extraction. There were few retinal detachments and, based on regression analysis, these cases would most likely have occurred with or without Verisyse implantation. Minimal endothelial cell loss (3.8%) was shown at the 3-year follow-up, showing the Verisyse is well tolerated in the eye. Additionally, no IOLs were removed because of chronic inflammation.


**Price:** We have implanted more than 100 Verisyse IOLs and have seen only two patients with slightly decreased endothelial cell counts and one of these cases may have been due to poor quality preoperative photographs, the other was possibly related to the surgery itself.

We have also implanted the Verisyse in patients who were outside the study parameters, such as those who required myopic correction greater than 20 D. There is also a significant difference between LASIK and phakic IOL implantation in highly myopic patients that is interesting. For example, it is common to worry about inducing visual loss in patients with high degrees of myopia with LASIK, whereas in my experience most patients with high myopia achieve an overall improvement in best-corrected vision with the Verisyse, and even if there is no improvement, there is no loss of visual acuity.

**Lindstrom:** Did you have any lens subluxations or power errors?

**Price:** We had one power error in a patient for whom we were basing the correction on the cycloplegic refraction. We had another power error in a patient who may have had an unstable refraction, or an unusual amount of accommodation. However, overall we have had excellent results with our power calculations.

When I perform LASIK for higher levels of myopia, I find that there is some variability.



**The most impressive aspect of the postoperative results was that 49% of the patients who had the Verisyse phakic IOL implanted gained one to two lines of visual acuity and 2% of patients gained more than two lines of BCVA.**

— R. Doyle Stulting, MD

However, in the Verisyse trials, the results were on target with our preoperative calculations. Considering that during the study, the Verisyse was available only in power steps of 1 D, these results are exceptional.

**Lindstrom:** Have you seen the postoperative inflammation course that is typical with cataract surgery?

**Price:** I have seen a lower incidence of postoperative inflammation with Verisyse implantations than with cataract surgeries. The only case where there would be more postoperative inflammation would be when there is bleeding from the peripheral iridotomy or complicated enclavation.

**Lindstrom:** Do you recommend a postoperative regimen of steroids or NSAIDs?

**Price:** Yes. I prescribe topical NSAIDs for 3 to 4 weeks and then discontinue them. I have seen some patients who have pigment deposition and have put them back on NSAIDs for a few weeks and this has always worked well. I have had no cases of persistent inflammation or pigment deposition.

### Transitioning to phakic IOL technology

**Lindstrom:** Dr. Donnenfeld, what is the learning curve with the Verisyse?

**Stulting:** The incision used for implanting the Verisyse IOL is one that all interior segment surgeons should be able to create without any difficulty. Additionally, astigmatically neutral incisions with suturing should be part of the anterior segment surgeon's skill set. The challenge will be proper placement of the IOL, the selection of the fixation point and mechanical incorporation of the iris to the haptics. The learning curve will involve bimanual dexterity and knowledge of the appropriate amount of iris tissue to use in enclavation. Anterior segment surgeons will be able to master these skills without difficulty.

**Donnenfeld:** Verisyse implantation is not difficult to learn. As with all intraocular surgeries, preparation is more important than the actual surgical procedure. If a surgeon understands the procedure before heading into the operating room — meaning that he or she has researched the procedure and has been trained well — it should only take one or two surgeries to become comfortable with implanting the Verisyse.

The experience that we have all had with the Verisyse is that our patients are among the most satisfied after surgery. These patients are not seeking cosmetic improvement. They are visually handicapped, and their lives are improved dramatically with a phakic IOL. The quality of vision that they obtain is better than they can achieve with any other procedure.

Patients in whom I have implanted the Verisyse phakic IOL have become my ambassadors for refractive surgery. They not only refer patients for phakic IOLs, but they also refer patients with lower degrees of myopia who are candidates for LASIK. I have found that postoperatively, patients who have received a phakic IOL are so enthused that they want to talk to everyone they know about their positive experience.

**Lindstrom:** How long did it take you to become comfortable with the implantation and enclavation procedure with the Verisyse?

**Price:** It took me approximately four or five procedures to feel comfortable with the procedure. However, I started implanting the Verisyse within the confines of a clinical trial. Surgeons now have the advantage of FDA approval, so it is easier to get together groups of patients for the procedure.

In phase 2 of the trial, we were implanting the Verisyse in sporadic populations of patients and waiting long periods of time between procedures.

**Davis:** We have found that results with the Verisyse IOL are predictable and stable.

In the study, we did not see significant or ongoing endothelial cell loss. Two patients experienced traumatic, non-spontaneous dislocations of the IOL — one whose wife struck him in the eye during a seizure and another who was punched in the eye. However, repositioning the IOLs was uneventful in both cases. Early in the study, a few patients experienced wound leaks that were managed with resuturing. One patient had the Verisyse removed because her boyfriend did not like the appearance of the IOL in her eye. No infections, cataract formations or losses of BCVA were seen, and many patients had consistent gains in lines of BCVA. Overall, a high rate of patient satisfaction was seen.


**Hunkeler:** I represent the cataract surgeon who, unlike a LASIK surgeon, is accustomed to older patients who are not always satisfied with the visual acuity that an IOL provides. Since I have started implanting the Verisyse, I have patients who are uniformly grateful for what I have been able to accomplish for their visual acuity and quality of life. For the cataract surgeon, phakic IOLs represent a new vista.

I implanted the Verisyse in 30 eyes and had one patient who had subluxation of the lens after she inadvertently flipped a towel and hit herself in the eye. Re-enclavation was simple and successful.

**Lindstrom:** A “wow” factor definitely exists with this procedure, even more so than with LASIK, provided the sutures are not so tight and that they induce astigmatism. Most patients in whom I implanted this lens see better on the first day without correction than they ever did with glasses.

**Stulting:** Patient word-of-mouth is always the most

stable and reliable source of marketing for any refractive procedure and this will be no different. This procedure will generate truly happy patients who will tell their friends, especially because the Verisyse IOL will be implanted in patients with the highest degrees of myopia. This procedure will change the quality of life for a patient who receives it. I enjoy seeing my phakic IOL patients because they invariably greet me with a smile and a thank you.



**I think that the greatest challenge is going to be getting office staff on board with the Verisyse IOL implantation procedure.**

— John D. Hunkeler, MD

**Davis:** The opportunity to market a practice through patient referrals from those who have undergone Verisyse implantation is great. In our practice, we hold patient seminars on refractive surgery in which the Verisyse IOL is one of the options and is recommended for patients who are too myopic to be candidates for LASIK.

Other marketing might include press releases or having office staff contact local newspapers to see if they are interested in running a story about phakic IOLs. Because patients have become savvy due to the information that is available on the Internet, I would recommend that surgeons who perform Verisyse implantation include it on their Web site.

**Lindstrom:** We also must inform referring ophthalmologists and optometrists about the phakic IOL

procedure so that they will be able to discuss it with their patients.

**Dr. Hunkeler,** what challenges does the cataract-only surgeon face in marketing phakic refractive IOL procedures?

**Hunkeler:** Rather than challenges, phakic IOLs provide an opportunity for surgeons who have only been performing cataract procedures to become involved in the refractive arena. The high level of patient satisfaction following phakic IOL implantation will be a new experience for cataract surgeons.

I think that the greatest challenge is going to be getting office staff on board with the Verisyse IOL implantation procedure.

**Lindstrom:** Will you market the Verisyse procedure externally?

**Hunkeler:** We have communicated directly in writing with information about the Verisyse and soon we will be having a seminar to discuss the Verisyse lens with our optometric referral doctors.

**Lindstrom:** Where are you positioning the value of the Verisyse procedure?

**Hunkeler:** I will place the Verisyse procedure somewhere between the crystalens (eyeonics, inc., Aliso Viejo, Calif.) accommodating IOL and a wavefront-guided LASIK procedure.

**Lindstrom:** I see Verisyse implantation as a premium procedure — it fits in the same category as RLE with an accommodating IOL.

**Donnenfeld:** I agree. The value of this procedure is well beyond anything we would offer patients with emmetropia or low refractive errors. Patients who are candidates for implantation with the Verisyse are the most visually handicapped patients we see in our practice and the need for this type of procedure is tremendous.

A surgeon will generally spend more time with patients who undergo phakic IOL implantation because of the longer informed consent and because currently, the procedure is performed unilaterally. Additionally, the postoperative care will involve more time initially, although in the long-term, follow-up will most likely take less time because the results with the Verisyse are so stable.

Financially speaking, I would place the Verisyse

procedure at approximately \$800 more than wavefront-guided LASIK and at the same price as an accommodating IOL.

**Davis:** I also agree that Verisyse implantation should be a premium-priced procedure, placed somewhere in the price range between LASIK and RLE. Patients should understand that IOL implantation is an invasive procedure that will be done in the operating room with nurses and anesthetists caring for them. Knowing this will help them understand and appreciate the cost of the procedure. Additionally, I agree with Dr. Donnenfeld that a majority of patients who will undergo this procedure have a severe visual handicap, so they know that it is no small feat to correct it.

**Price:** A Verisyse IOL procedure involves more costs than laser refractive procedures and includes the surgeon's fee, facility fees, anesthetist's fee and the cost of the IOL. So it should not be priced the same as LASIK.

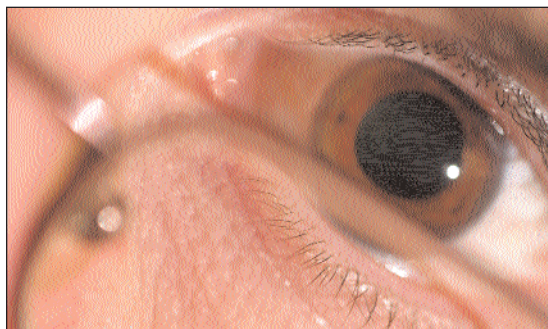**Lindstrom:** Surgeons who choose to perform phakic IOL implantation will differentiate their practices from other ophthalmologists' in that offering the newest technology involves additional skill and training.

**Hunkeler:** There are surgeons in the ophthalmic community who have distinguished themselves as premium. For example, if I were a patient in the Minneapolis/St. Paul area, I would expect you to offer the latest, best technology in anterior segment surgery. Surgeons who have distinguished themselves in that way enjoy the higher reputation that they have and want to maintain that.

I have just begun performing LASIK but feel that the technology is such that the learning curve has rapidly accelerated to increase my comfort with this procedure. To properly help our patients achieve the best results with refractive surgery and with refractive cataract surgery, one must offer LASIK as an adjunct to optimize the outcome. This is why I have begun performing LASIK — to compliment the other procedures with which I have been involved.


**Lindstrom:** Dr. Donnenfeld, even though you perform various types of ophthalmic surgery, you are widely known as a refractive surgeon. Do you see the FDA approval of the Verisyse IOL as a big step for the refractive surgeon?

**Donnenfeld:** This is the biggest step in refractive surgery since the introduction of the excimer laser. We have seen incremental improvements in excimer laser technology with myopia, hyperopia, astigmatism and wavefront-guided procedures, but these have been small changes. This is the first procedure that is completely different and I believe it



**Patients who are candidates for implantation with the Verisyse are the most visually handicapped patients we see in our practice and the need for this type of procedure is tremendous.**

— Eric D. Donnenfeld, MD



will serve as a launching pad for future technological inventions and improvements that will change the landscape of refractive surgery. Having phakic IOLs and RLE technology allows the refractive surgeon now to be more comprehensive.

Many refractive surgeons have made the error of being solely laser surgery practitioners, ignoring cataract surgery. Just as Dr. Hunkeler stated that phakic IOLs will allow cataract surgeons to venture into the world of refractive surgery, so will this procedure be a bridge for refractive surgeons to cataract procedures.

While phakic IOL procedures are not suitable for every ophthalmic surgeon, the majority of experts in cataract and refractive surgery will adapt to this procedure because it has such an important role.

**Davis:** Premium surgeons should be able to offer patients a variety of options for refractive surgery. If all you have is a hammer, then everything looks like a nail. In the case of refractive surgery, when there are multiple methods of approaching correction available, being adept at all of these procedures ensures a greater chance that the patient will have the safest and best visual outcome. So, rather than looking at LASIK as the only option for a patient with higher refractive error and a slightly suspicious topography, a surgeon will be able to offer a better option within phakic IOL implantation.

**Lindstrom:** As technology has evolved during the years in which I have performed refractive surgery, I have learned that it is important to decide which procedure to recommend to a patient, because if a patient is presented with too many options, they lose confidence in the ability of the surgeon. An ophthalmologist should say to a patient, “You could have LASIK or have a phakic IOL, but for your particular case, I recommend ...” The ophthalmologist cannot remain neutral because patients trust us to know what is best for their visual outcome.

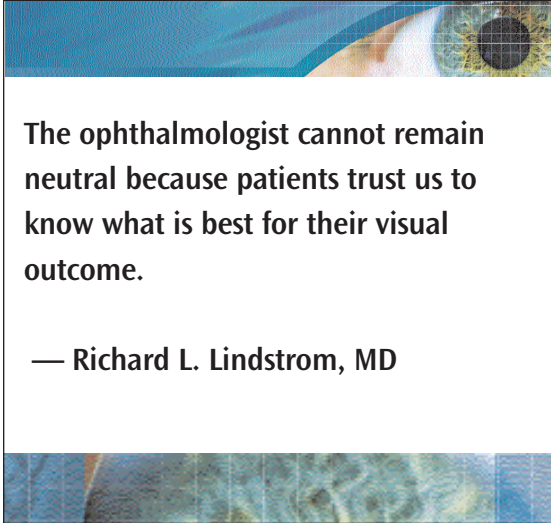
### Future

**Lindstrom:** This year has been crucial to lens-based refractive surgery. RLE procedures are becoming more common, the first accommodative IOL, the crystalens, was approved and we now have the first FDA-approved phakic IOL. What impact will this have on laser refractive surgery?

**Stulting:** Phakic IOLs will expand the refractive surgical market. I do not see phakic IOL implantation as competition for LASIK, but rather an addition to our armamentarium. For every patient who has a phakic IOL lens implant instead of LASIK, there will be an additional patient who is not a LASIK candidate but who has a phakic IOL lens implant followed by LASIK enhancement.

In the future, I would like to see a foldable version of the Verisyse IOL and instrumentation to make implantation easier.

**Price:** The quality of vision with phakic IOLs is precise and pristine. Just a few changes to the Verisyse could possibly make the IOL adjustable once it is in



**The ophthalmologist cannot remain neutral because patients trust us to know what is best for their visual outcome.**

— Richard L. Lindstrom, MD

the eye. This would be a significant technological advance.

**Donnenfeld:** I see phakic IOLs as important to the future of refractive surgery and a technology that will have a significant impact on the base of patients who undergo refractive procedures.

It will not be long before foldable, astigmatic phakic IOLs become available.

**Davis:** I agree that foldable, toric and multifocal phakic IOLs will be available in the near future. In the more distant future, phakic IOLs will be adjustable and adaptable to wavefront platforms.

**Hunkeler:** Once we have an adjustable phakic IOL, the bar will be raised significantly for refractive surgery. There is a fear factor to refractive surgery and such technology would help potential patients conquer that fear.

**Lindstrom:** Phakic IOLs are an exciting innovation in ophthalmology and I look forward to watching how they will impact refractive surgery.

I would like to thank the faculty members for their participation in this interesting symposium, OCULAR SURGERY NEWS for organizing the meeting and AMO for its support.

### Reference

1. Sarver EJ, Sanders DR, Vukich JA. Image quality in myopic eyes corrected with laser in situ keratomileusis and phakic intraocular lens. *J Refract Surg.* 2003;19(4):397-404.

