

# Keratoconus and Corneal Ectasia After LASIK

Perry S. Binder, MS, MD; Richard L. Lindstrom, MD; R. Doyle Stulting, MD, PhD; Eric Donnenfeld, MD; Helen Wu, MD; Peter McDonnell, MD; Yaron Rabinowitz, MD

**K**eratoconus is a naturally occurring ectatic corneal disorder in which the cornea progressively thins and steepens to produce myopia, irregular astigmatism, and eventually, loss of best spectacle-corrected visual acuity. Reported risk factors for keratoconus include eye rubbing, a family history of keratoconus, genetic predisposition, Down's syndrome, ocular allergy, connective tissue disease, and contact lens wear. Pellucid marginal degeneration and keratoglobus are other non-inflammatory corneal thinning disorders.<sup>1</sup>

Progressive thinning and steepening of the cornea may also occur after LASIK. This condition, commonly referred to as post-LASIK ectasia, behaves in a manner similar to that of keratoconus.<sup>2</sup>

This document is the 2005 consensus opinion of a committee of seven refractive surgeons brought together at the request of the American Academy of Ophthalmology, the International Society for Refractive Surgery, and the American Society of Cataract and Refractive Surgery to summarize current knowledge of ectatic corneal disorders and ectasia after LASIK.

## ECTATIC CORNEAL DISORDERS

Ectatic corneal disorders (including keratoconus and ectasia after LASIK) are the second most common indications for keratoplasty, accounting for about 15% of corneal transplants performed in the United States.<sup>3</sup> Based on epidemiologic studies, the incidence of keratoconus is estimated to be approximately 1 in 2000 in

the general population.<sup>4</sup> The incidence of ectasia after LASIK is unknown, as accurate data are unavailable.<sup>5</sup>

If corneal ectasia develops, there are many options available for treatment before an eye becomes a candidate for penetrating keratoplasty. These include soft contact lenses (spherical and toric), rigid gas permeable lenses (spherical, bitoric, reverse geometry), scleral contact lenses, intracorneal ring segments (INTACS),<sup>6</sup> and lamellar keratoplasty. The percentage of eyes that have developed ectasia after laser vision correction and have required a corneal transplant is unknown.

We think that if an eye progresses to penetrating keratoplasty, the prognosis for vision in that eye is the same whether the ectatic condition developed de novo or as a result of laser vision correction. Corneal transplantation for keratoconus has the highest success rate of any indication, with graft survival rates of 97% and 92% at 5 and 10 years, respectively.<sup>7</sup> We think that based on our combined clinical corneal transplant experience that the visual prognosis for patients who undergo penetrating keratoplasty for ectasia is excellent; the majority of these patients should be able to achieve normal quantitative and qualitative visual function without restriction.

Traditionally, keratoconus has been diagnosed by slit-lamp findings, including corneal thinning, Fleischer rings, stress lines, and scarring. Recently, more sophisticated methods of measuring corneal topography have allowed identification of eyes with unusual topographic patterns, but no slit-lamp findings or loss of best spectacle-corrected visual acuity. It is not known currently whether eyes with these patterns in the normal population will progress to develop ectatic corneal disorders or remain unchanged throughout life.<sup>8</sup> It is our firm opinion that the diagnosis of corneal ectatic disorders is a clinical one that can only be made by careful examination of the eye, as there is no definitive blood test, clinical marker, or single examination technique that can establish a specific diagnosis, although videokeratography can be useful to confirm the diagnosis in clinical disease.

Just as we recognize risk factors for keratoconus and

*From Gordon Binder Weiss Vision Institute, San Diego, Calif (Binder); Minnesota Eye Consultants, Minneapolis, Minn (Lindstrom); Emory University, Atlanta, Ga (Stulting); Ophthalmic Consultants of Long Island, Rockville Centre, NY (Donnenfeld); Tufts New England Medical Center, Boston, Mass (Wu); Wilmer Ophthalmological Institute, Johns Hopkins University School of Medicine, Baltimore, Md (McDonnell); and Cornea Genetic Eye Institute, Cedars Sinai Medical Center, Los Angeles, Calif (Rabinowitz).*

*Correspondence: Perry S. Binder, 8910 University Center Lane, Suite 800, San Diego, CA 92122. Tel: 858.455.6800; Fax: 858.455.0244; E-mail: garrett23@aol.com*

*Received: October 26, 2005*

*Accepted: October 27, 2005*

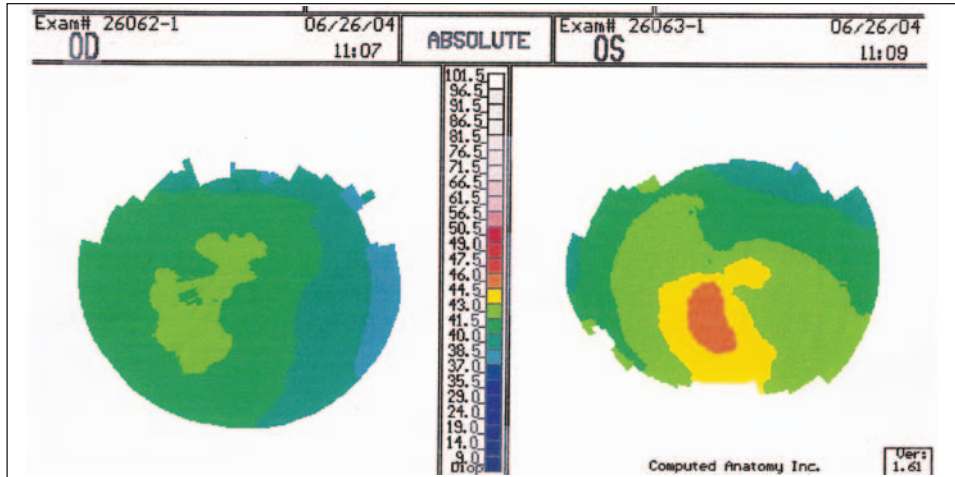
TABLE  
**Current Risk Factors for  
 Corneal Ectatic Disorders**

Prominent corneal nerves
Fleischer ring (iron line)
Scissoring of the retinoscopic reflex
Patterns of topography (*forme fruste keratoconus)
Family history of keratoconus
Keratoconus in one eye
Asymmetric, thin corneas
Asymmetric astigmatism
Asymmetric, steep corneas
Irregular astigmatism
Tilted (skewed) keratometry mires
Vogt's striae
Thinning of the cornea
Apical scarring of the cornea
Corneal irregularity that cannot be corrected by spectacles

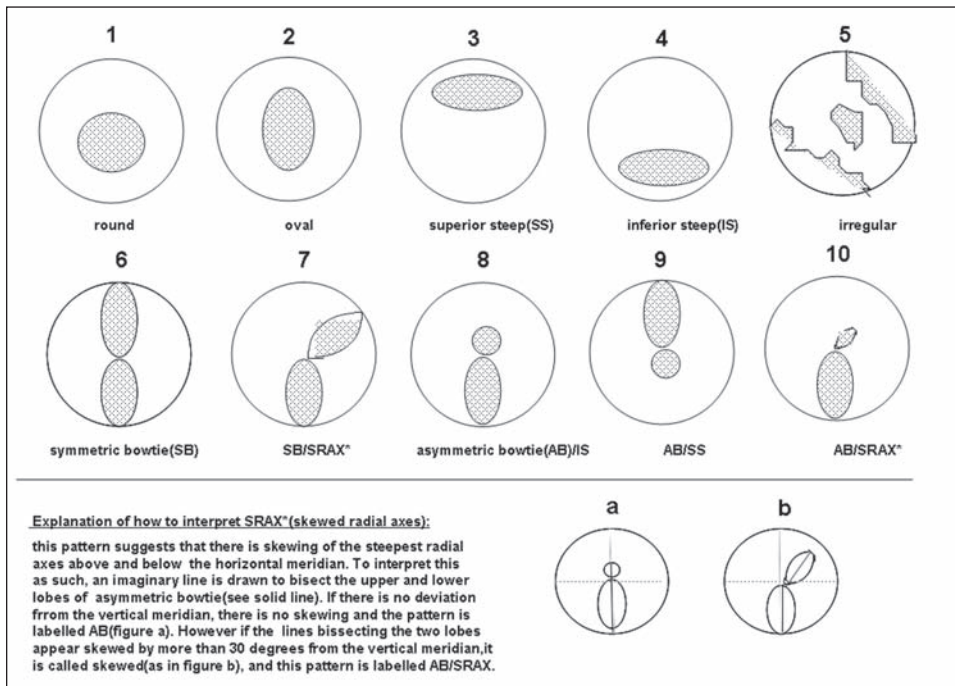
other ectatic conditions (Table), possible risk factors for the development of ectasia following laser vision correction have been identified in the published literature. These include high myopia, reduced preoperative corneal thickness, reduced residual stromal bed after laser ablation, and asymmetrical corneal steepening (forme fruste keratoconus), but none of these characteristics definitively predict the development of ectasia.<sup>9</sup> Ectasia can develop in eyes with no currently identifiable risk factors.

### CONCLUSIONS

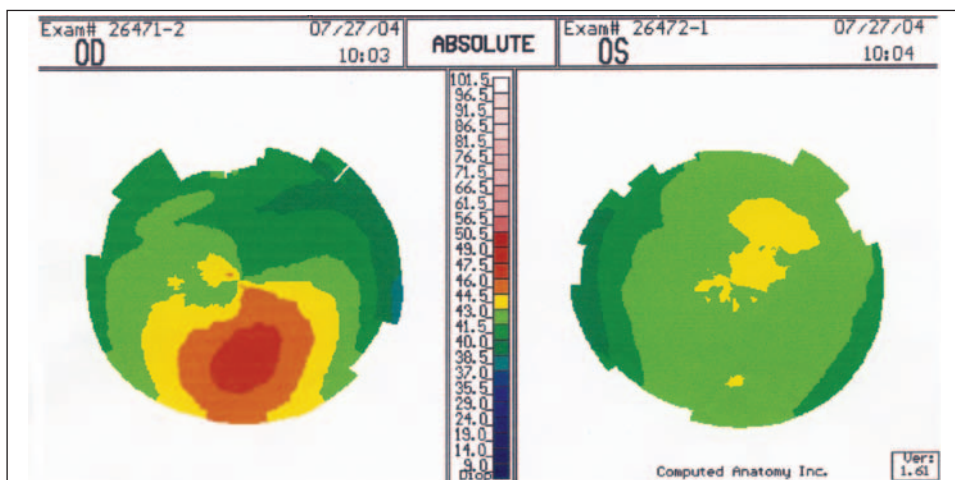
1. Although different stages of keratoconus can be diagnosed by slit-lamp examination, more sensitive analyses of corneal topography and thickness reveal a continuum of findings from those that are clearly normal to those that are clearly pathologic. There is no specific test or measurement that is diagnostic of a corneal ectatic disorder. Because subtle corneal curvature changes can be overlooked on slit-lamp evaluation and videokeratography has been shown to be useful to confirm a diagnosis preoperatively, videokeratography should be performed prior to corneal refractive surgery.
  2. A computer-generated diagnosis of "keratoconus suspect" based on indices specific to certain instruments is not necessarily a contraindication to vision correction surgery. A decision to perform LASIK should take the entire clinical picture into account, as such
- topographically based, computer-generated warnings may occur in the presence of normal corneas.
3. Although some risk factors have been suggested for ectasia after LASIK, none of them are absolute predictors of its occurrence. Thus, the occurrence of ectasia after laser vision correction per se is not a deviation from the standard of care.
  4. Because keratoconus may develop in the absence of refractive surgery, the occurrence of ectasia after LASIK does not necessarily mean that LASIK was a causative or contributing factor for its development
  5. Little information exists on the results of surface ablation in eyes with risk factors for ectasia after LASIK, so risk factors for ectasia after LASIK may not also predict ectasia after surface ablation.
  6. Ectasia is a known risk of laser vision correction, and if ectasia occurs in a patient following laser vision correction it does not necessarily mean that the patient was a poor candidate for surgery, that the surgery was contraindicated, or that there was a violation of the standard of care.
  7. Forme fruste keratoconus is a topographic diagnosis, rather than a clinical one. It is not a variant of keratoconus. Rather, forme fruste implies subclinical disease with the potential for progression to clinically evident keratoconus. The existing literature on ectasia and longitudinal studies of the fellow eye of unilateral keratoconus patients indicates that asymmetrical inferior corneal steepening, or asymmetric bowtie topographic patterns with skewed steep radial axes above and below the horizontal meridian (Figs 1-4), are risk factors for progression to keratoconus and ectasia after LASIK. We now recommend against performing LASIK on such patients using current technology. Patients with these topographic patterns who are stable could be offered photorefractive keratectomy (PRK) with informed consent, indicating that there may still be a risk of progression to keratoconus. Patients with an inferior "crab claw" pattern accompanied by central flattening ("blue spot") are at risk for the development of pellucid marginal degeneration, even if there are no clinical signs of it (see Fig 4). This pattern should be designated "pellucid suspect," and LASIK should be avoided in eyes exhibiting this topographic pattern.
  8. Although no formal guidelines have existed to date and good scientific data for future guidelines are presently lacking, based on the review of the literature and the current body of knowledge available in 2005, to reduce some of the risks for ectasia after LASIK, we recommend that surgeons review topography prior to surgery. Intraoperative pachymetry to



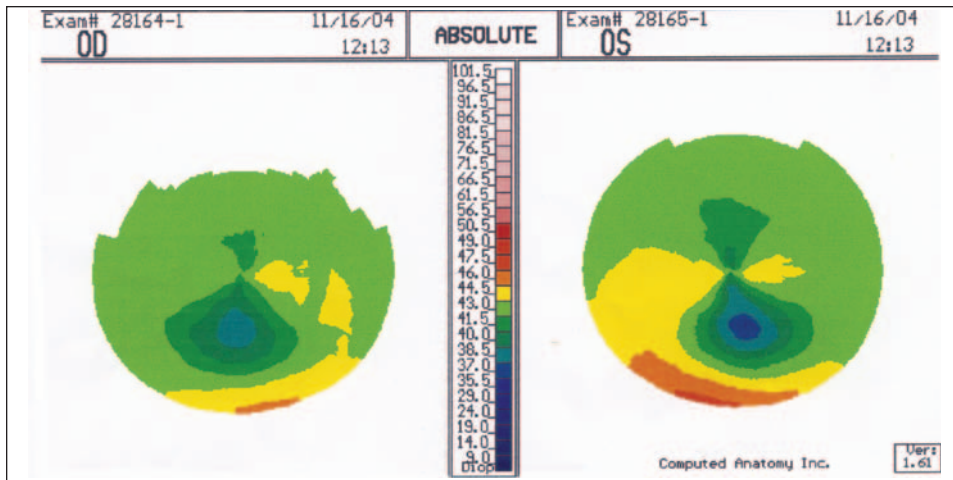
**Figure 1.** Videokeratography map of the left eye in the absolute scale demonstrates forme fruste keratoconus in a family member of a patient with keratoconus, illustrating an asymmetric bowtie pattern with skewed steep radial axes above and below the horizontal meridian (very mild AB/SRAX pattern). The right eye of the same patient demonstrates normal appearing topography. Similar patterns can be seen in normal patients with contact lens warpage and in 0.5% of the normal non contact lens-wearing population.<sup>10</sup>



**Figure 2.** Diagrammatic representation of various videokeratography patterns in the normal population in the absolute scale to illustrate interpretation of the asymmetric bowtie with skewed steep radial axes above and below the horizontal meridian (AB/SRAX) pattern. (Reproduced with permission from Rabinowitz et al. Videokeratography database of normal human corneas. *Br J Ophthalmol.* 1996;80:610-616. Copyright © 1996.)



**Figure 3.** Videokeratography map of a patient with "early" keratoconus in the right eye with an asymmetric bowtie with skewed steep radial axis above and below the horizontal meridian (AB/SRAX) pattern.<sup>10</sup> The topography in the left eye appears normal.



**Figure 4.** Videokeratography maps of a patient with “pellucid marginal degeneration suspect” topography and against-the-rule astigmatism in the left eye. Note the central “blue spot” depicting central flattening and an incomplete inferior “crab claw” appearance commonly seen in patients with clinical pellucid marginal degeneration.

determine flap thickness should be considered for cases in which the calculated residual stromal bed might be near the safe lower limits for the procedure and/or the reproducibility of the microkeratome might result in a residual stromal bed less than those limits.

#### REFERENCES

1. Rabinowitz YS. Keratoconus. *Surv Ophthalmol.* 1998;42:297-319.
2. Binder PS. Ectasia after laser in situ keratomileusis. *J Cataract Refract Surg.* 2003;29:2419-2429.
3. EBAA Statistical Report. 2004.
4. Kennedy RH, Bourne WM, Dyer JA. A 48-year clinical and epidemiologic study of keratoconus. *Am J Ophthalmol.* 1986;101:267-273.
5. ASCRS Member Survey. Post LASIK Ectasia. April 13, 2003. San Francisco, Calif.
6. Colin J, Velou S. Current surgical options for keratoconus. *J Cataract Refract Surg.* 2003;29:379-386.
7. Thompson RW Jr, Price MO, Bowers PJ, Price FW Jr. Long-term graft survival after penetrating keratoplasty. *Ophthalmology.* 2003;110:1396-1402.
8. Li X, Rabinowitz YS, Rasheed K, Yang H. Longitudinal study of the normal eyes in unilateral keratoconus patients. *Ophthalmology.* 2004;111:440-446.
9. Randleman JB, Russell B, Ward MA, Thompson KP, Stulting RD. Risk factors and prognosis for corneal ectasia after LASIK. *Ophthalmology.* 2003;110:267-275.
10. Rabinowitz YS, Yang H, Brickman Y, Akkina J, Riley C, Rotter JI, Elashoff J. Videokeratography database of normal human corneas. *Br J Ophthalmol.* 1996;80:610-616.

#### EDITOR'S NOTE

This article also appears in the November 2005 issue of the *Journal of Cataract and Refractive Surgery*.

#### AUTHOR QUERIES

The subhead “Ectatic Corneal Disorders” was added to break up the text. Is this okay as edited?

Please provide more information for reference 3, ie, please spell out EBAA.

Please provide documentation stating that permission was granted to reprint Figure 2. Also, please provide the name of the publisher of the *British Journal of Ophthalmology*.

The Editor’s Note may change, as I need to discuss this with the managing editor of JCRS. Once finalized, I will send for your review.